

## DIAGNOSIS OF *CAPILLARIA HEPATICA* IN *RATTUS RATTUS* BY HISTOPATHOLOGY

MARIA JEOVÂNIA FREIRE DE ALMEIDA-SILVA,  
CLAUDIA DEL FAVA, MARCOS POTENZA, FABRÍCIO REIS,  
AND ANA EUGENIA DE CARVALHO CAMPOS

Centro de Pesquisa e Desenvolvimento de Sanidade Animal, Vegetal e Ambiental. Instituto Biológico, Av. Conselheiro Rodrigues Alves 1252, Bairro Vila Mariana, CEP 04014-002, São Paulo/SP/Brasil; Aluna do Programa de Pós-Graduação - Mestrado *stricto sensu* em Sanidade, Segurança Alimentar e Ambiental no Agronegócio, Instituto Biológico

**Abstract** The present study diagnosed diseases present in *Rattus rattus* by histopathology. The material consisted of 43 specimens captured in the eastern city of São Paulo – Brazil. The animals were necropsied, and the organs were processed histologically and stained with hematoxylin-eosin. Microscopic analysis showed in the vicinity of portal spaces, eggs and elliptic operculated poles in different states of maturation, with thick walls in different layers, as well as parasitic nematodes. The morphological study of eggs classified the parasite as belonging to the species *Capillaria hepatica*. A total of 30 (69.8%) rodents were infected. Considering that *R. rattus* is an indoor rodent, which allows a closer contact with humans, further detailed studies of the role of this species as a transmitter of zoonosis are necessary.

**Key Words** Capillariasis, zoonosis, rodents

### INTRODUCTION

The roof rat (*Rattus rattus*) is found in all Brazilian states, and occurs in dry environment, always close to human houses (Bonvicino et al., 2008). Besides the morphological differences, roof rats show different behavior and habitats from the rat (*R. norvegicus*). Its dispersion in urban areas has been facilitated by the characteristics of the large cities of vertical buildings and the decoration of modern office buildings, suspended ceilings and galleries for wires and cables that provide them shelter and movement. In some Brazilian cities like Rio de Janeiro and São Paulo, the presence of the roof rat is increasing and prevalent in neighborhoods where previously dominated the rat, possibly because the control programs are directed to this latter species (Funasa, 2002).

*Capillaria hepatica* is a parasitic nematode (roundworm) which causes hepatic capillariasis in rodents and numerous other mammal species, with rare reported instances of human infections (Centers for Disease Control and Prevention, 2011). Rodents are the main reservoirs of *C. hepatica* (Acha and Szifres, 2003). The parasite has a direct life cycle that requires only one host. Adult worms invade the liver of the host (usually rodents, but may also be pigs, carnivores and primates, including humans), and lay hundreds of eggs in the surrounding parenchyma. The eggs are not passed in the feces of the host, and remain in the liver until the animal dies and decomposes, or it is eaten by a predator or scavenger. Eggs ingested by such an animal are unembryonated, are not infectious, and are passed in the feces, providing an efficient mechanism to release eggs into the environment. Cannibalism has been reported as an important role in transmission among rodent populations. Eggs embryonate in the environment, where they require air and damp soil to become infective, and under optimal conditions, this takes about 30 days. The cycle continues when embryonated eggs are eaten by a suitable mammalian host, and the infective eggs hatch in the intestine, releasing larvae. The larvae migrate via the portal vein to the liver, and take about four weeks to mature into adults and mate. Humans are usually infected after ingesting embryonated eggs in fecal-contaminated food, water, or soil, and occasionally larvae will migrate to the lungs, kidneys, or other organs (Centers for Disease Control and Prevention, 2011). In Brazil, some studies of capillariasis in rodents have been performed. It was related in *R. norvegicus* (Araújo, 1967; Galvão, 1981), and in *R. rattus* (Chieffi et al., 1981).

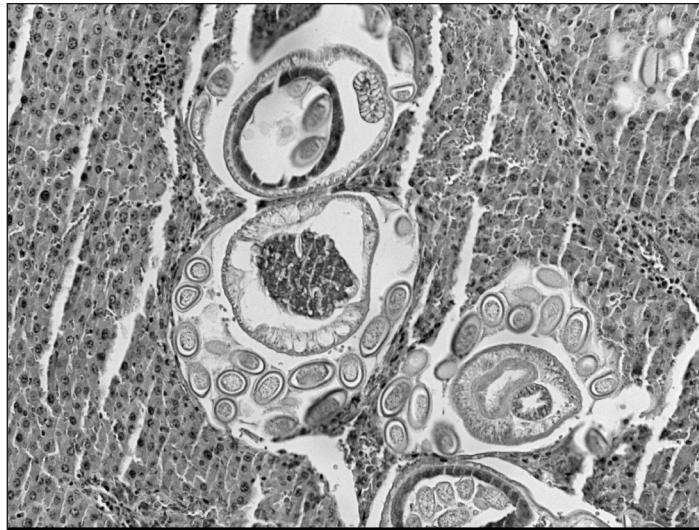
The present study aimed at reporting diseases present in *Rattus rattus* by histopathology exams, as well as describing pathological changes.

## MATERIALS AND METHODS

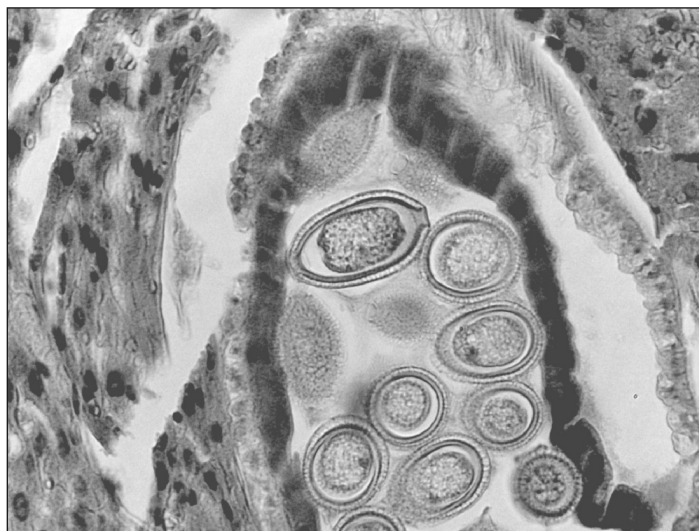The analyzed material consisted of 43 specimens of *R. Rattus* captured in the eastern city of São Paulo – Brazil. The animals were necropsied and samples of organs were collected for histopathology. Tissues were fixed in 10% buffered formalin, embedded in paraffin, cut at 4  $\mu\text{m}$ , and stained with hematoxylin and eosin (HE) for routine histology (Prophet et al., 1995).

## RESULTS AND DISCUSSION

It was observed that 69.8% (30/43) individuals presented histological changes in the liver caused by *C. hepatica*. Main gross findings included firm liver slightly increased in volume, with irregular capsular and cut surfaces due to multifocal and punctate yellow-whitish lesions which different diameters. Microscopic examination showed in the vicinity of portal spaces the presence of several elliptic and bioperculated ova, with polar eminence at each



**Figure 1.** Portal spaces with *Capillaria hepatica* ova in different states of maturation, and parasitic nematodes circumscribed by connective tissue associated with mononuclear inflammatory cells and eosinophils.



**Figure 2.** Elliptic and bioperculated ova, with polar eminence at each end, characteristic of *C. hepatica*.

end, in different states of maturation, as well as nematodes, and all these parasitic structures were circumscribed by connective tissue associated with mononuclear inflammatory cells and eosinophils (Figure 1). The hepatic parenchyma also showed alteration of lobular architecture, hepatocyte trabecular disarray, edema in some areas, and degeneration of hepatocytes. Some lesions were necrotic and calcified, with no parasitic structures. The morphological aspects of the ova allowed classifying the parasite as belonging to the species *C. hepatica* (Jones et al., 1997) (Figure 2).

The right rate of roof rats parasited by *C. hepatica* shows the potential risk of transmission of this zoonosis, especially considering that *R. rattus* is an indoor rodent, which allows a closer contact with humans, being important the adoption of measures of rodents control based on the public health point of view.

## CONCLUSIONS

Further detailed studies of the role of *R. rattus* in human environment, as potential risk for transmitting capillariasis and other zoonosis are necessary.

## REFERENCES CITED

- Acha, P.N. and Szifres B. Capillariasis. 2003.** In: Acha, P.N. and Szifres, B., eds. Zoonosis y enfermedades transmisibles comunes al hombre y a los animales. 3rd. ed., v.III. Parasitosis. Washington: Organización Panamericana de la Salud. Publicación Científica y Técnica n. 580.
- Araújo, P. 1967.** Helminhos de *Rattus norvegicus* (Berkenhout, 1769) da cidade de São Paulo. Rev. Fac. Farm. Bioquím. 5: 141-159.
- Bonvicino, C.R., Oliveira, J.A., and D'Andrea, P.S. 2008.** Guia dos roedores do Brasil, com chaves para gêneros baseadas em caracteres externos. Rio de Janeiro: Centro Pan-Americano de Febre Aftosa – OPAS/OMS.
- Centers for Disease Control and Prevention - CDC. 2011.** Capillariasis. Atlanta: CDC. <http://www.cdc.gov/parasites/capillaria/index.html> (Mar. 13, 2011).
- Chieffi, P.P., Dias, R.M.D.S., Mangini, A.C.S., Grispino, D.M.A., and Pacheco, M.A.D. 1981.** *Capillaria hepatica* (Bancroft, 1893) em murídeos capturados no município de São Paulo, SP, Brasil. Rev. Inst. Med. Trop. 23: 143-146.
- Funasa. 2002.** Manual de Controle de Roedores. Brasília: Fundação Nacional de Saúde.
- Galvão, V.A. 1981.** Estudos sobre *Capillaria hepatica*: uma avaliação do seu papel patogênico para o homem. Mem. Inst. Oswaldo Cruz. 76: 415-433.
- Jones, T.C., Hunt, R.D., and King, N.W. 1997.** Veterinary Pathology. 6<sup>st</sup>. ed. Baltimore: Lippincott Williams and Wilkins.
- Prophet, E.B., Mills, B., Arrington, J.B., and Sobin, L.H. 1995.** Métodos Histotecnológicos. Washington: Registro de Patologia de los Estados Unidos de América.

